

# Effect of Leaves and Fruits of *Moringa oleifera* on Gastric and Duodenal Ulcers

V.C. Devaraj<sup>1</sup>, Mohammed Asad<sup>1</sup>, and Satya Prasad<sup>2</sup>

<sup>1</sup>Krupanidhi College of Pharmacy, Bangalore, India; <sup>2</sup>MNR Medical College, Andhra Pradesh, India

## Abstract

The effect of different extracts of leaves and fruits of *Moringa oleifera* Lam. (Moringaceae) on gastric and duodenal ulcers was evaluated by using different gastric ulcer models and cysteamine-induced duodenal ulcer method. The leaf extracts (500 mg/kg, p.o.) of *Moringa oleifera* showed gastric ulcer healing effect in acetic acid-induced chronic gastric ulcers. The acetone extract and methanol extract of the leaves produced gastric anti-secretory effect in pylorus-ligated rats and showed gastric cytoprotective effect in ethanol-induced and indomethacin-induced gastric ulcers. The leaf extracts also produced a significant reduction of stress-induced gastric ulcers and cysteamine-induced duodenal ulcers. None of the extracts of the fruits showed any significant antiulcer effect. It was concluded that leaves of *Moringa oleifera* increase healing of gastric ulcers and also prevent the development of experimentally induced gastric ulcers and duodenal ulcers in rats.

**Keywords:** Duodenal ulcer, gastric cytoprotection, gastric secretion, gastric ulcer, *Moringa oleifera* Lam.

## Introduction

Peptic ulcer is a breach in the gastric and duodenal epithelium associated with acute or chronic inflammation and is the most common gastrointestinal disorder in clinical practice. In spite of established antiulcer drugs, a rational therapy for peptic ulcer remains elusive, and a search for safer potential drugs is being carried out. The use of natural drugs in gastric ulcer has been reported (Sairam et al., 2001).

The development and progression of gastric ulcer depends to some extent on the type of the food consumed

by the patient. It has been shown that spicy food, fatty food, or food containing caffeine stimulates acid secretion in the stomach (Crawford, 2003), and high-fiber diets such as potatoes, bananas, peas, beans, and so forth, reduce the development of duodenal ulcers (Maryland Medical Center Programs, 2004).

Previous reports on the incidence of gastric ulcers in the South Asian population reveals that the occurrence is lower due to the type of food consumed by the people of this region; one of the foods that is speculated to protect against ulcers is *Moringa oleifera* Lam. (Moringaceae) leaves (Jayaraj et al., 1998). Furthermore, flower bud of *Moringa pterygosperma*, a synonym of *Moringa oleifera* that is widely consumed in Pakistan, has been reported to possess antiulcer activity against aspirin-induced gastric ulcers in rats (Akhtar & Ahmad, 1995). However, the effect of different extracts of leaves or fruits of *Moringa oleifera* on gastric and duodenal ulcers is not known. The current study was undertaken to evaluate the effect of fruits and leaves of *Moringa oleifera* on experimentally induced gastric and duodenal ulcers.

## Materials and Methods

### Collection of plant material and extraction procedure

The leaves and fruits of *Moringa oleifera* were collected from the Madiwala area of Bangalore, India, in the month of May and were authenticated by the Regional Research Institute (Bangalore, India). A voucher specimen (RRI/BNG/SMP-Prog/800) has been preserved in the Regional Research Institute for future reference.

The shade-dried leaves and fruits of the plant were subjected to Soxhlet extraction, and the extracts thus

Accepted: November 13, 2006.

Address correspondence to: Dr. Mohammed Asad, Department of Pharmacy, Krupanidhi College of Pharmacy, #5, Sarjapur Road, Koramangala, Bangalore 560 034, India; E-mail: mohammedasad@rediffmail.com

obtained were subjected to preliminary phytochemical analysis (Mukaherjee, 2002).

### Experimental animals

Albino Wistar rats weighing between 200 and 250 g were used. The institutional animal ethics committee approved the experimental protocol. Animals were maintained under standard conditions in an animal house approved by the Committee for the Purpose of Control, and Supervision on Experiments on Animals (CPCSEA), Government of India.

### Acute toxicity study

The acute oral toxicity study was performed according to the OPPTS (Office of Prevention, Pesticide and Toxic Substance) Up and Down procedure (Health Effect Test Guideline, 2004). The different extracts were suspended using 0.5% sodium carboxy methylcellulose and were administered orally. All the extracts of leaves and fruits were safe at a dose of 5000 mg/kg, p.o., and one-tenth of this dose was selected for evaluation of antiulcer activity.

### Effect on gastric ulcers

#### *Acetic acid-induced chronic gastric ulcer*

Male Wistar rats were fasted for 24 h prior to the experiment. Under light ether anesthesia, a midline epigastric incision was made and the stomach was exposed. Glacial acetic acid (0.05 mL) was applied topically onto the serosal surface using a cylindrical mold (6.0 mm internal diameter), which was allowed to remain there for 60 s. The acid solution was then removed by rinsing the mold with normal saline to prevent possible damage to the surrounding tissues close to the point of application. The animals were treated with different extracts of leaves and fruits of *Moringa oleifera* (500 mg/kg, p.o.) once daily for 10 days after induction of ulcer while the control group received only vehicle. Rats were sacrificed on the 10th day by overdose of ether anesthesia; stomach was removed and cut open along the greater curvature (Okabe et al., 1970).

The stomach samples were scanned using a computer scanner, and the total mucosal area and total ulcerated area were measured using public domain image processing and analysis program developed at National Institutes of Health (Bethesda, MD, USA). The PC version of the program was downloaded free from Scion (<http://www.scioncorp.com>; Scion Image for Windows, release beta 4.0.2). The scale was set at 6.1 pixels per millimeter.

The ulcer index was determined using the formula (Ganguly, 1969)

$$\text{Ulcer index} = 10/X$$

where X = total mucosal area/total ulcerated area.

The ulcers were given scores based on their intensity as follows: 0 = no ulcer, 1 = superficial mucosal erosion, 2 = deep ulcer or transmural necrosis, 3 = perforated or penetrated ulcer.

The stomach samples from groups that showed reduction in ulcer index were subsequently processed for histologic examination. Three indices, namely regenerated glandular epithelial width, capillary density in the scar tissue, and volume of collagen content were selected to reflect the rate and quality of ulcer healing (Wang et al., 1999).

#### *Pylorus ligation-induced ulcers*

The animals were fasted for 36 h with water *ad libitum* before pylorus ligation (Shay et al., 1945; Kulkarni, 1999). Normal saline (1 mL/rat, p.o.) was administered twice daily to all the animals during the fasting period (Asad et al., 2003). Under light ether anesthesia, the pyloric portion of the stomach was ligated. The leaf extracts (500 mg/kg, p.o.) were administered intraduodenally immediately after pylorus ligation. Six hours after pylorus ligation, animals were sacrificed. The stomach was isolated and the content of the stomach was used for estimation of free and total acidity (Hawk et al., 1947), pepsin content (Debnath et al., 1974), total hexoses (Goel et al., 1985), and total proteins (Lowry et al., 1951). The ulcer index was determined using the same method as mentioned earlier.

#### *Healing of indomethacin-induced gastric ulcers*

The gastric ulcers were induced by administering indomethacin (5 mg/kg, p.o.) for 5 days to the normally fed animals (Majumdar et al., 2003). The animals were then treated with different extracts of leaves of *Moringa oleifera* (500 mg/kg, p.o.) once daily for 5 days after induction of ulcer while the control group received only vehicle. The last dose of indomethacin was considered day 0. Rats were sacrificed on the day 0 and day 5. The stomach was removed; ulcer score and ulcer index were determined. The glandular portion of the stomach was then used for estimation of mucin content (Corne et al., 1974), total proteins (Lowry et al., 1951), antioxidant factors like superoxide dismutase activity (Elstner & Heupel, 1976), total tissue sulfhydryl groups (Ellman, 1959), and catalase activity (Link, 1988).

#### *Ethanol-induced ulcers*

Male albino rats were fasted for 36 h before administration of 90% ethanol (1 mL/200 g). The leaf extracts (500 mg/kg, p.o.) were administered 1 h before ethanol

administration. One hour after ethanol administration, the animals were sacrificed, stomach was isolated, and ulcer index was determined (Brzozowski et al., 1998).

### Cold restraint stress-induced ulcers

The animals were placed in a restraint cage, and the cage was placed at a temperature of 2°C for 3 h. The leaf extracts (500 mg/kg, p.o.) were administered 30 min prior to subjection of stress. The animals were sacrificed, stomach was isolated, and ulcer index was determined (Vincent et al., 1977).

### Effect on duodenal ulcers

#### Cysteamine-induced duodenal ulcers

Duodenal ulcers were induced by administering cysteamine hydrochloride (400 mg/kg, p.o.) twice at an interval of 4 h. Leaf extracts (500 mg/kg, p.o.) were administered 30 min prior to each dose of cysteamine hydrochloride. After 24 h of the first dose of cysteamine, animals were sacrificed and the duodenum was excised carefully and cut opened along the antimesenteric side. The duodenal ulcer area, ulcer score, and ulcer index were determined (Szabo, 1978).

The ulcers were given scores based on their intensity as follows: 0 = no ulcer, 1 = superficial mucosal erosion, 2 = deep ulcer or transmural necrosis, 3 = perforated or penetrated ulcer.

The ulcer index (UI) was calculated using the following equation (Desai et al., 1999):

$$\text{UI} = \text{Arithmetic mean of intensity in a group} + \frac{\text{Number of ulcer positive animals}}{\text{Total number of animals}} \times 2$$

### Statistical analysis

The statistical significance was assessed using one-way analysis of variance (ANOVA) followed by Dunnett's comparison test. For comparing nonparametric ulcer scores, ANOVA followed by non-parametric Dunn post test was used. The values are expressed as mean  $\pm$  SEM, and  $p < 0.05$  was considered significant.

## Results

### Acetic acid-induced chronic gastric ulcers

The petroleum ether, acetone, and methanol leaf extracts of *Moringa oleifera* showed a significant reduction in ulcer index when compared with control ( $p < 0.001$ ). The acetone extract of the leaves was most potent; it produced a 79% decrease in the ulcer index. The fruit

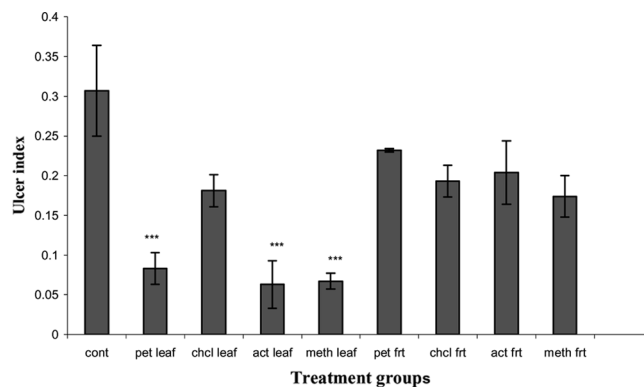


Figure 1. Effect of *Moringa oleifera* on ulcer index in acetic acid-induced chronic gastric ulcer. All values are mean  $\pm$  SEM,  $n = 5$  to  $6$ . \* $p < 0.05$ , \*\* $p < 0.01$ , \*\*\* $p < 0.001$  when compared with control group. Cont, control; pet leaf, petroleum ether leaf extract (500 mg/kg p.o.); chcl leaf, chloroform leaf extract (500 mg/kg p.o.); act leaf, acetone leaf extract (500 mg/kg p.o.); meth leaf, methanol leaf extract (500 mg/kg); pet frt, petroleum ether fruit extract (500 mg/kg p.o.); chcl frt, chloroform fruit extract (500 mg/kg p.o.); act frt, acetone fruit extract (500 mg/kg); meth frt, methanol fruit extract (500 mg/kg p.o.).

extracts of *Moringa oleifera* and the chloroform extract of the leaves did not show any significant effect on ulcer index (Fig. 1). None of the treatments produced any significant effect on ulcer score (Fig. 2).

Histologic examination of the ulcerated area revealed that there was a significant increase in regenerated glandular epithelium width after treatment with acetone extract of the leaves ( $p < 0.05$ ) when compared with control. The collagen content in the ulcerated tissue was significantly increased by all the three extracts of

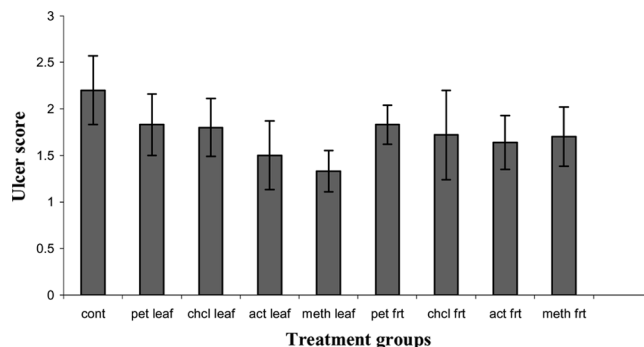


Figure 2. Effect of *Moringa oleifera* on ulcer score in acetic acid-induced chronic gastric ulcer. All values are mean  $\pm$  SEM,  $n = 5$  to  $6$ . \* $p < 0.05$ , \*\* $p < 0.01$ , \*\*\* $p < 0.001$  when compared with control group. Cont, control; pet leaf, petroleum ether leaf extract (500 mg/kg p.o.); chcl leaf, chloroform leaf extract (500 mg/kg p.o.); act leaf, acetone leaf extract (500 mg/kg p.o.); meth leaf, methanol leaf extract (500 mg/kg); pet frt, petroleum ether fruit extract (500 mg/kg p.o.); chcl frt, chloroform fruit extract (500 mg/kg p.o.); act frt, acetone fruit extract (500 mg/kg); meth frt, methanol fruit extract (500 mg/kg p.o.).

Table 1. Effect of *Moringa oleifera* Lam. on regenerated glandular epithelium width, capillary density, and volume of collagen content in acetic acid-induced chronic gastric ulcers.

Treatment	Regenerated glandular epithelium width ( $\mu\text{m}$ )	Capillary density (no.) in $19,600 \mu\text{m}^2$	Volume of collagen content
Control	$504 \pm 60.39$	$5.4 \pm 0.51$	$0.182 \pm 0.018$
Petroleum ether leaf extract (500 mg/kg, p.o.)	$564 \pm 46.48$	$6.6 \pm 0.81$	$0.262 \pm 0.014^{**}$
Acetone leaf extract (500 mg/kg, p.o.)	$700 \pm 20.94^*$	$4.6 \pm 1.89$	$0.291 \pm 0.009^{***}$
Methanol leaf extract (500 mg/kg, p.o.)	$588 \pm 24.98$	$4.0 \pm 1.05$	$0.266 \pm 0.012^{**}$

All values are mean  $\pm$  SEM, n = 5 to 6. \*p < 0.05, \*\*p < 0.01, \*\*\*p < 0.001 when compared with control group.

the leaves, with acetone extract showing the maximum effect. No significant difference on capillary density in scar tissue was observed after treatment (Table 1).

### Pylorus ligation-induced gastric ulcers

The acetone leaf extracts of *Moringa oleifera* showed a significant reduction in free acidity and total acidity when compared with control (p < 0.05) whereas the methanol extract of the leaves showed significant reduction only in free acidity (p < 0.05). None of the treatments produced any significant effect on ulcer index, total hexose content, mucin content, pepsin activity, and total protein (Table 2).

### Healing of indomethacin-induced gastric ulcers

The acetone and methanol leaf extracts of *Moringa oleifera* showed a significant reduction in ulcer index (p < 0.01) and a significant increase in mucus content when compared with control. None of the treatments produced any significant effect on total protein and antioxidant factors like SOD activity, total tissue sulfhydryl group (glutathione), and catalase activity (Table 3).

### Ethanol-induced gastric ulcers

The acetone and methanol leaf extracts of *Moringa oleifera* showed a significant reduction in ulcer index when compared with control (p < 0.05). The petroleum ether extract did not show significant reduction in ulcer index when compared with control (Table 4).

### Stress-induced gastric ulcers

All the three leaf extracts of *Moringa oleifera* showed a significant reduction in ulcer index when compared with control. Again, the acetone extract of the leaves was most potent in reducing ulcer index (Table 4).

### Cysteamine-induced duodenal ulcers

The acetone leaf extract of *Moringa oleifera* showed a highly significant reduction in ulcer area when compared

with control (p < 0.01). The methanol leaf extracts of *Moringa oleifera* showed a significant reduction in ulcer area when compared with that of control (p < 0.05). The petroleum ether leaf extract did not show any significant reduction in ulcer area. None of the treatments produced any significant effect on ulcer score and ulcer index (Table 4).

## Discussion

The current study dealt with the effect of different extracts of *Moringa oleifera* leaves and fruits on the gastric and duodenal ulcers in rats. The extracts that showed ulcer-healing effect in acetic acid-induced gastric ulcers were screened further to determine their effect on gastric cytoprotection and gastric secretion.

Application of glacial acetic acid (0.05 mL) on to the serosal surface of the rat stomach produces deep penetrating gastric ulcers (Okabe et al., 1971). The fruit extracts of the plant did not show any effect on the healing of gastric ulcers induced by acetic acid, whereas the petroleum ether, acetone, and methanol leaf extracts of *Moringa oleifera* increased healing of the acetic acid-induced gastric ulcers. The histopathologic examination was carried out to determine the effect of extracts on regeneration of glandular epithelium, formation of collagen, and capillary density, all of which are essential processes for the healing of ulcers. The acetone extract of the leaves increased the collagen content and regeneration of glandular epithelium, whereas the methanol and petroleum ether extract of the leaves produced only an increase in collagen content.

Pylorus ligation-induced ulcer was used to study the effect of extracts on gastric secretion. The ligation of the pyloric end of the stomach causes accumulation of gastric acid in the stomach that produces ulcers in the stomach. Agents that decrease gastric acid secretion and/or increase mucus secretion are effective in protecting the ulcers induced by this method. The acetone and methanol extracts of *Moringa oleifera* produced reduction in gastric acid secretion proving their anti-secretory effect.

Table 2. Effect of *Moringa oleifera* leaf extracts on free acidity, total acidity, ulcer index, and total hexoses in pylorus-ligated rats.

Treatment	Free acidity (mEq/L)	Total acidity (mEq/L)	Ulcer index	Total hexoses	Mucin content	Pepsin content	Total protein
Control	6.74 ± 0.3581	13.78 ± 0.765	0.098 ± 0.019	1.98 ± 0.231	6.92 ± 0.376	0.163 ± 0.011	54.49 ± 8.01
Petroleum ether leaf extract (500 mg/kg, p.o.)	4.90 ± 0.8370	14.04 ± 1.233	0.058 ± 0.008	2.12 ± 0.330	7.6 ± 2.240	0.172 ± 0.034	51.32 ± 4.30
Acetone leaf extract (500 mg/kg, p.o.)	4.04 ± 0.454*	8.83 ± 1.765*	0.058 ± 0.010	1.56 ± 0.287	7.60 ± 1.154	0.085 ± 0.023	74.85 ± 14.96
Methanol leaf extract (500 mg/kg, p.o.)	3.75 ± 0.430*	10.23 ± 0.742	0.098 ± 0.025	2.213 ± 0.330	7.66 ± 1.63	0.143 ± 0.277	71.78 ± 13.22

All values are mean ± SEM, n = 5 to 6. \*p < 0.05, \*\*p < 0.01 when compared with control group.

Table 3. Effect of *Moringa oleifera* leaf extracts on indomethacin-induced ulcers.

Treatment	Mucin content	Ulcer index	Total protein	SOD units/mg protein	Glutathione units/mg of protein	Catalase units/mg of protein
Control	14.03 ± 4.69	0.1034 ± 0.008	22.82 ± 7.13	136.84 ± 43.32	0.110 ± 0.015	105.16 ± 51.07
Petroleum ether leaf extract (500 mg/kg, p.o.)	34.92 ± 7.691	0.1049 ± 0.021	32.54 ± 2.18	61.73 ± 3.63	0.081 ± 0.051	32.18 ± 7.39
Acetone leaf extract (500 mg/kg, p.o.)	50.09 ± 9.78**	0.0263 ± 0.005**	35.48 ± 3.83	58.79 ± 5.23	0.263 ± 0.079	40.60 ± 15.20
Methanol leaf extract (500 mg/kg, p.o.)	48.92 ± 7.76*	0.0531 ± 0.0065*	36.06 ± 8.13	63.83 ± 18.58	0.032 ± 0.007	34.86 ± 5.89

All values are mean ± SEM, n = 5 to 6. \*p < 0.05, \*\*p < 0.01 when compared with control group.

Table 4. Effect of *Moringa oleifera* leaf extracts in ethanol-induced gastric ulcers, stress-induced gastric ulcers, and cysteamine-induced duodenal ulcers.

Treatment	Ethanol induced	Stress induced	Cysteamine induced		
	Ulcer index	Ulcer index	Ulcer index	Ulcer area	Ulcer score
Control	0.496 ± 0.057	0.2100 ± 0.0379	7.5	5.50 ± 0.258	2.0 ± 0.3651
Petroleum extract leaf extract (500 mg/kg, p.o.)	0.151 ± 0.054	0.1204 ± 0.0153*	5.8	3.83 ± 0.872	2.2 ± 0.3073
Acetone leaf extract (500 mg/kg, p.o.)	0.133 ± 0.044*	0.0849 ± 0.0168**	4.0	2.00 ± 0.258**	1.3 ± 0.2108
Methanol leaf extract (500 mg/kg, p.o.)	0.142 ± 0.045*	0.1271 ± 0.01511*	4.9	2.92 ± 0.712*	1.3 ± 0.2108

All values are mean ± SEM, n = 5 to 6. \*p < 0.05 when compared with control group.

Ethanol-induced and indomethacin-induced gastric ulcer was employed to study the cytoprotective effect of the extracts. The acetone and methanol extracts of *Moringa oleifera* leaves were effective in reducing ulcer index in both these models and significantly increased the mucus content in indomethacin-induced gastric ulcers. However, the leaf extracts of *Moringa oleifera* were not effective in altering the antioxidant factors like SOD activity, total tissue sulfhydryl group (glutathione), and catalase activity suggesting that the healing of ulcers or prevention of development of gastric ulcers may not be due to antioxidant effect.

Stress plays an important role in ulcerogenesis. The pathophysiology of stress-induced gastric ulcers is complex. Stress-induced ulcers are probably mediated by histamine release with enhancement in acid secretion and a reduction in mucus production (Brodie & Hanson, 1960; Peters & Richardson, 1983). The petroleum ether, acetone, and methanol extracts of *Moringa oleifera* were effective in reducing the ulcers induced by stress. Cysteamine-induced duodenal ulcer in rat is a widely used model of peptic ulcer disease. Cysteamine hydrochloride inhibits the alkaline mucus secretion from the Brunner glands in the proximal duodenum and stimulates gastric acid secretion rate. Gastric emptying is also delayed, and serum gastrin concentration is increased (Parmar & Desai, 1993). The acetone and methanol leaf extracts of *Moringa oleifera* were effective in reducing the ulcer area in cysteamine-induced duodenal ulcers.

The acetone and methanol extracts of the leaves were effective in all the tested models of peptic ulcer disease, whereas the petroleum ether was effective only in healing chronic gastric ulcers and stress-induced gastric ulcers. Hence, the healing of gastric ulcers in acetic acid-induced gastric ulcers may be due to decreased acid secretion, increased mucus secretion, or decreased GI motility in case of acetone and methanol extracts, and the ulcer healing in case of petroleum ether may be mainly due to reduction in gastric motility.

*Moringa oleifera* contains a number of flavonoids, triterpenes, steroids, alkaloids, and many other chemical constituents (Ross, 1999). The flavonoid quercetin present in the leaves is a well-known antiulcer agent

(Suzuki et al., 1998). Further, the leaves contain rutin, a flavonoid that is reported to have gastric cytoprotective effect (Casa et al., 2000). This explains more potent ulcer healing effect of acetone and methanol extracts of the leaves compared with petroleum extract. Apart from flavonoids, the leaves of the plant contain steroids such as  $\beta$ -sitosterol and  $\beta$ -carotene, and both of these are known to reduce the development of gastric ulcers (Xiao et al., 1992). This probably explains the activity of petroleum ether extract.

The results of the current study suggest that consumption of the leaves of *Moringa oleifera* may be beneficial in healing of ulcers in patients suffering from peptic ulcer disease.

## Acknowledgment

The authors are thankful to Prof. Suresh Nagpal, chairman, Krupanidhi Educational Trust, and Prof. Sunil Dhaminigi, secretary, Krupanidhi Educational Trust, for providing facilities to carry out the work. The authors are also thankful to Prof. Dr. Amit Kumar Das, principal, Krupanidhi College of Pharmacy, for his valuable suggestions during the work.

## References

- Akhtar AH, Ahmad KU (1995): Anti-ulcerogenic evaluation of the methanolic extracts of some indigenous medicinal plants of Pakistan in aspirin-ulcerated rats. *J Ethnopharmacol* 46: 1–6.
- Asad M, Rajesh KS, Ahmad M (2003): Effect of administration of saline or glucose during fasting on the development of gastric ulcers in pylorus ligated rats. *Ethiop Pharm J* 16: 1–6.
- Brodie DAQ, Hanson HM (1960): A study of the factors involved in the production of gastric ulcers by the restraint technique. *Gastroenterology* 38: 353–360.
- Brzozowski T, Konturek SJ, Kwiecien S, Pajdo R, Brzozowski I, Hahn EG (1998): Involvement of endogenous cholecystokinin and somatostatin in gastro

- protection induced by intra duodenal fat. *J Clin Gastroenterol* 27: 125–137.
- Casa CL, Villegas I, Lastra CA, Motilva V, Calero MJM (2000): Evidence for protective and antioxidant properties of rutin, a natural flavone, against ethanol induced gastric lesions. *J Ethnopharmacol* 71: 45–53.
- Corne SJ, Morrissey SM, Woods RJ (1974): A method for the quantitative estimation of gastric barrier mucus. *J Physiol* 242: 116–117.
- Crawford JM (2003): *Robbin's Pathologic Basis of Disease*. New Delhi, India, Saunders, pp. 787–802.
- Debnath PK, Gode KO, Govinda DD, Sanyal AK (1974): Effect of propranolol on gastric secretion in rats. *Br J Pharmacol* 51: 213–216.
- Desai JK, Goyal RK, Parmar NS (1999): Characterization of dopamine receptor subtypes involved in experimentally induced gastric and duodenal ulcers in rats. *J Pharm Pharmacol* 51: 187–192.
- Ellman GL (1959): Tissue sulfhydryl groups. *Arch Biochem Biophys* 82: 70–77.
- Elstner EF, Heupel A (1976): Inhibition of nitrite formation from hydroxyl ammonium chloride. A simple assay for super oxide dismutase. *Anal Biochem* 70: 616–620.
- Ganguly AK (1969): A method for quantitative assessment of experimentally produced ulcers in stomach of rats. *Experientia* 25: 1224.
- Goel RK, Das DG, Sanyal AK (1985): Effect of vegetable banana powder on changes induced by ulcerogenic agents in dissolved mucosubstances of gastric juice. *Indian J Gastroenterol* 4: 249–251.
- Hawk PB, Oser BL, Summerson HW (1947): *Practical Physiological Chemistry*, 12th ed. London, Churchill, p. 347.
- Health Effect Test Guidelines (2004): Acute Oral Toxicity [computer program], OPPTS 870, 1100 United States Office of Prevention, Pesticides and Toxic Substances, Environmental Protection Agency (7101). Available at <http://www.epa.gov/opptsfrs/home/guidelin.htm>.
- Jayaraj AP, Tovey FI, Clark CG (1998): Possible dietary protective factors in relation to the distribution of duodenal ulcer in India and Bangladesh. *Gut* 21: 1068–1076.
- Kulkarni SK (1999): *Handbook of Experimental Pharmacology*, 3rd ed. New Delhi, India, Vallabh Prakashan, pp. 148–150.
- Link EM (1988): Mechanism of pH dependent hydrogen peroxide cytotoxicity *in vitro*. *Arch Biochem Biophys* 265: 362–372.
- Lowry CH, Roseborough NI, Farr AL, Randall RJ (1951): Protein measurement with Folin phenol reagent. *J Biol Chem* 193: 265–275.
- Majumdar B, Chaudhri SGR, Ray A, Bandyopadhyay SK (2003): Effect of ethanol extract of *Piper betle* Linn leaf on healing of NSAID-induced experimental ulcer—A novel role of free radical scavenging action. *Indian J Exp Biol* 41: 311–315.
- Maryland Medical Center Programs (2004): Peptic ulcers. Available at [http://www.umm.edu/patiented/articles/what\\_lifestyle\\_changes\\_recommended\\_pepticulcers\\_dyspepsia\\_000019\\_11.htm](http://www.umm.edu/patiented/articles/what_lifestyle_changes_recommended_pepticulcers_dyspepsia_000019_11.htm).
- Mukaherjee PK (2002): *Quality Control of Herbal Drugs (An Approach to Evaluation of Botanicals)*. New Delhi, Business Horizons, pp. 380–421.
- Okabe S, Pfeiffer CJ, Roth JL (1970): Experimental production of duodenal and antral ulcers in rats. *Federal Proc* 29: 255.
- Okabe S, Roth JLA, Pfeiffer CJ (1971): Differential-healing periods of the acetic acid ulcer model in rats and cats. *Experientia* 27: 146–148.
- Parmar NS, Desai JK (1993): A review of the current methodology for the evaluation of gastric and duodenal anti-ulcer agents. *Indian J Pharmacol* 25: 120–135.
- Peters MN, Richardson CT (1983): Stressful life events, acid hyper secretion, and ulcer disease. *Gastroenterology* 84: 114–119.
- Ross IA (1999): *Medicinal plants of the World*. New Jersey, Humana Press, 234–235.
- Sairam K, Rao ChV, Goel R K (2001): Effect of *Centella asiatica* Linn on physical and chemical factors induced gastric ulceration and secretion in rats. *Indian J Exp Biol* 39: 137–142.
- Shay H, Komarov SA, Fele SS, Meranze D, Gruenstein H, Sipler H (1945): A simple method for uniform production of gastric ulceration in rat. *Gastroenterology* 5: 43–61.
- Suzuki Y, Ishihara M, Segami T, Ito M (1998): Anti-ulcer effects of antioxidants, quercetin,  $\alpha$ -tocopherol, nifedipine and tetracycline in rats. *Jpn J Pharmacol* 78: 435–441.
- Szabo S (1978): Animal model for human disease: Duodenal ulcer disease. *Am J Pathol* 73: 273–276.
- Vincent GP, Galvin GB, Rutkowski JL, Pare WP (1977): Body orientation, food deprivation and potentiation of restraint induced gastric lesions. *Gastroenterol Clin Biol* 1: 539–543.
- Wang JZ, Wuy J, Rao CM, Gao MT, Li WG (1999): Effect of recombinant human basic fibroblast growth factor on stomach ulcers in rats and mice. *Acta Pharmacol Sin* 209: 763–768.
- Xiao M, Yang Z, Jiu M, You J, Xiao R (1992): The anti-gastroulcerative activity of  $\beta$ -sitosterol- $\beta$ -D-glucoside and its aglycone in rats. *Hua Xi Yi Ke Da Xue Xue Bao* 23(1): 98–101.

Copyright of *Pharmaceutical Biology* is the property of Taylor & Francis Ltd and its content may not be copied or emailed to multiple sites or posted to a listserv without the copyright holder's express written permission. However, users may print, download, or email articles for individual use.



Copyright of *Pharmaceutical Biology* is the property of Taylor & Francis Ltd and its content may not be copied or emailed to multiple sites or posted to a listserv without the copyright holder's express written permission. However, users may print, download, or email articles for individual use.